



DATE **PRESENTING CLINICAL SIGNS**
1/13/23 ultrasound showed undefined nodular splenic and hepatic changes; FNA of spleen and liver today.
R/O neoplasia ; suspect benign nodular hyperplasia

INTERPRETED BY **CYTOLOGY SUBMISSION**
L.D. McGill, DVM,
Ph.D, DACVP FNA of t Liver & Spleen

PATIENT **OBSERVATIONS**
Percy Goldstein Liver: Submitted are 5 excellent videos of moderate to excellent collections of cells from the liver in Percy. The hepatocytes demonstrate vacuoles and mild granularity. There are scattered lymphocytes in the surrounding RBCs. They are mainly mature small lymphocytes. Neutrophils are few in numbers. Malignant characteristics are not identified.
SPECIES Spleen: Submitted are 8 excellent videos of large numbers of RBCs with very few nucleated cells. The nucleated cells are mixed with scattered neutrophils and lymphocytes. There are no malignant characteristics in these cells.
Canine

BREED **INTERPRETATION OF THE FINDINGS & FURTHER RECOMMENDATIONS**
maltese mix Liver - Hepatocellular vacuolization with mild lymphocytic collections.
Spleen - Congested spleen with mixed cell collection

SEX **COMMENTS**
Male Neutered The changes in the liver suggest metabolic liver disease with the possibility of lymphocytic cholangiohepatitis. There is no suggestion of malignancy in the liver. The lymphocytes could be the result of lymphoma of the small cell type, but further evaluation will be required to confirm that diagnosis. At this time, I do not think that is the underlying process. The changes in the spleen suggest congestion and mixed cell collection which is nonspecific. Continued evaluation of organs in the abdominal cavity is encouraged to attempt to identify a primary process when very likely these two organs are responding secondarily.
AGE 7 years

WEIGHT
n/a

HOSPITAL NAME
Mt Olive Veterinary
Hospital

REFERRING VET
Dr. Logan

INVOICE NUMBER
40639



DATE

1/13/23

INTERPRETED BY

L.D. McGill, DVM,
Ph.D, DACVP

PATIENT

Percy Goldstein

SPECIES

Canine

BREED

maltese mix

SEX

Male Neutered

AGE

7 years

WEIGHT

n/a

HOSPITAL NAME

Mt Olive Veterinary
Hospital

REFERRING VET

Dr. Logan

INVOICE NUMBER

40639

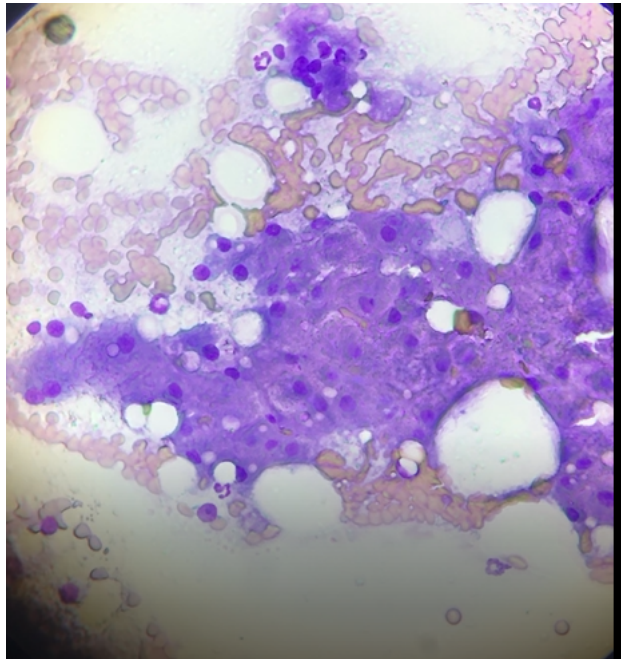


Image shows liver with vacuoles and scattered lymphocytes collected from the liver in Percy. There are scattered neutrophils.

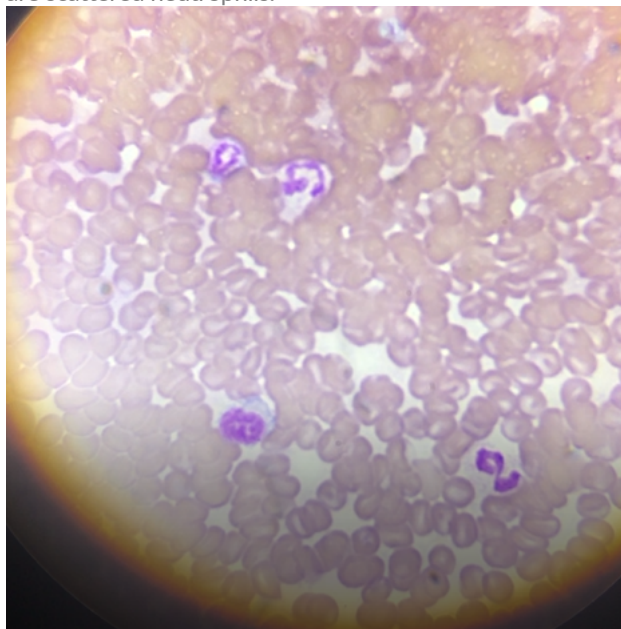


Image shows RBCs and a mixture of cells with prominent neutrophils collected from the spleen in Percy. There is no suggestion of malignancy.

The information and recommendations provided are based on the images presented by the referring veterinarian. No evaluation can be communicated regarding pathology that was not visible in the image/video clips provided.



DATE 1/13/23 Thank you for this referral. If the clinical or image interpretation does not parallel your findings or if I can be of any further assistance, please contact me.

INTERPRETED BY L.D. McGill, DVM, Ph.D., DACVP
8288 Top of the World Drive
Cottonwood Heights, UT 84121
ldmcgill.vetpath@gmail.com
cell: 801-865-1220

PATIENT
Percy Goldstein

SPECIES
Canine

BREED
maltese mix

SEX
Male Neutered

AGE
7 years

WEIGHT
n/a

HOSPITAL NAME
Mt Olive Veterinary
Hospital

REFERRING VET
Dr. Logan

INVOICE NUMBER
40639